

# Cerebellar Bacterial Brain Abscess: Report of Eight Cases

Che-Wei Hsu<sup>1</sup>, Chen-Hsien Lu<sup>1</sup>, Ming-Jung Chuang<sup>2</sup>, Chi-Ren Huang<sup>1</sup>, Yao-Chung Chuang<sup>1</sup>,  
Nai-Wen Tsai<sup>1</sup>, Shu-Fang Chen<sup>1</sup>, Chung-Chih Chang<sup>1</sup>, Wen-Neng Chang<sup>1</sup>

## Abstract-

**Purpose:** To analyze the clinical characteristics and therapeutic outcome of patients with solely cerebellar bacterial brain abscess (BBA).

**Case Report:** Eight patients with solely cerebellar BBA, collected during a period of 23 years from 210 BBA patients, were included in this study. The eight patients were five men and three women, aged 5-54 years (mean, 36.6 years). Six of them were adults, one was a child, and one was an adolescent. Six patients had underlying medical/surgical problems. Of the clinical presentations, dizziness was the most common (87.5%, 7/8), followed by headache (62.5%, 5/8), altered consciousness (62.5%, 5/8), fever (50%, 4/8), ataxia (25%, 2/8), hearing impairment (12.5%, 1/8), dysarthria (12.5%, 1/8), and hemiparesis (12.5%, 1/8). The Image Severity Index (ISI) scores of these eight patients ranged from 6 to 12 points. All eight patients received both medical and surgical treatment. One patient died owing to a complication in the neurosurgical procedure and the remaining patients survived. The therapeutic outcome was quantified one month after discharge by modified Rankin scale (mRS) and the result showed six of the seven survivors had good outcomes, while the other one had a poor outcome (ataxic gait).

**Conclusion:** Cerebellar BBA accounted for 3.8% (8/210) of the overall BBA. In cerebellar BBA, dizziness is a frequent symptom. Early diagnosis and a combination of antimicrobial and neurosurgical intervention is important for its treatment. The small case number is a limitation of this study; therefore, further large-scale study of cerebellar BBA is needed for better delineation of the clinical characteristics, therapeutic outcome, and prognostic factors.

**Key Words:** bacterial brain abscess, cerebellum, image severity index, prognosis

*Acta Neurol Taiwan 2011;20:47-52*

## INTRODUCTION

Bacterial brain abscess (BBA) is a localized suppurative process and it can evolve rapidly, causing a devastating outcome<sup>(1-3)</sup>. Most BBAs are located in the cere-

bral hemispheres, and cerebellar abscess is relatively uncommon<sup>(1,2,4,5)</sup>. The smaller volume of the posterior fossa usually ensures a higher tendency of cerebellar herniation and/or brainstem compression; therefore, the clinical features and therapeutic strategy of this specific

From the Departments of <sup>1</sup>Neurology, <sup>2</sup>Neurosurgery, Chang-Gung Memorial Hospital-Kaohsiung Medical Center; Chang Gung University College of Medicine, Kaohsiung, Taiwan.  
Received March 17, 2010. Revised April 27, 2010.  
Accepted July 29, 2010.

Correspondence to: Wen-Neng Chang, MD. Department of Neurology, Chang Gung Memorial Hospital-Kaohsiung, No. 123, Ta Pei Road, Niao Sung Hsiang, Kaohsiung Hsien, Taiwan.  
E-mail: cwenneng@ms19.hinet.net

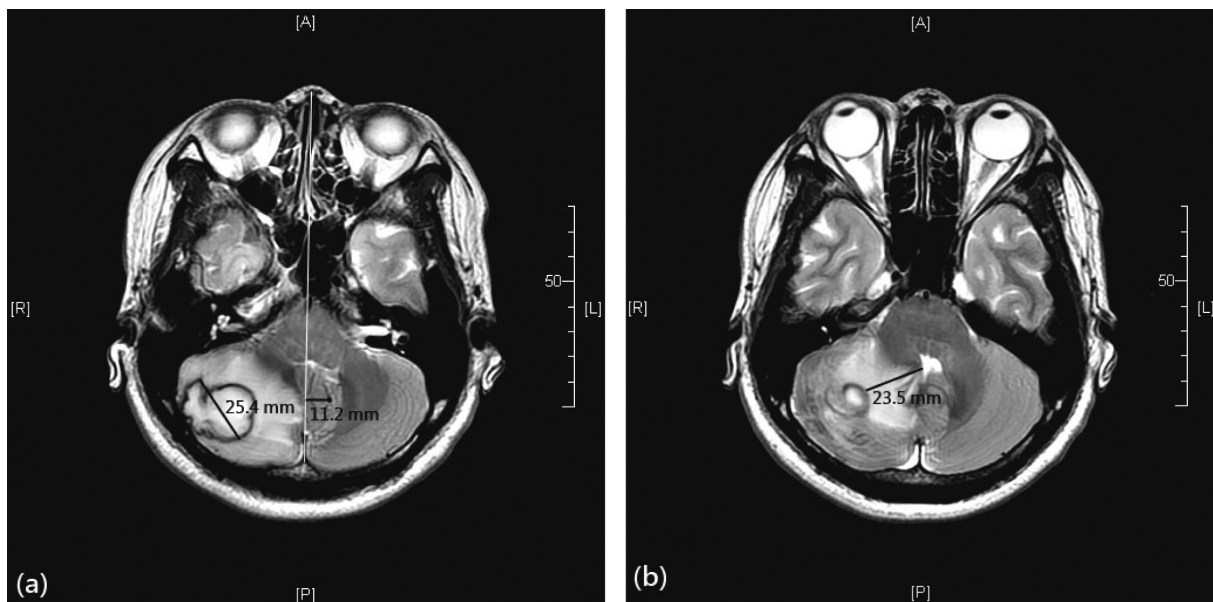
central nervous system infection deserves special consideration<sup>(6,7)</sup>. Because cerebellar BBA is uncommonly examined solely in the literature, in this study, we retrospectively analyzed the clinical characteristics and therapeutic outcome of eight patients with solely cerebellar BBA.

## CASE REPORT

Over a period of 23 years (January 1986 to December 2007), 210 patients were found to have BBA in Chang Gung Memorial Hospital (CGMH)-Kaohsiung. Of these 210 patients, eight patients had solely cerebellar BBA, and were thus included in the study. In this study, the inclusion criteria of BBA<sup>(1)</sup> were as follows: (1) characteristic computerized tomography (CT) and/or magnetic resonance imaging (MRI) findings; (2) evidence of brain abscess seen during surgery or histopathologic examination; and (3) classical clinical manifestations including headache, fever, localized neurologic signs, and/or consciousness disturbance.

The basic clinical data of the eight patients with cerebellar BBA are listed in Table 1. The eight patients included five men and three women, aged 6-54 years (mean = 36.6 years). Of these eight patients, six patients were adults, one patient was a child, and the remaining one was an adolescent. Except for Patients 4 and 5, the other 6 patients had an underlying medical or surgical problem as the preceding event. Of the clinical presentations, dizziness was found in seven patients; headache, in five patients; altered consciousness, in five patients; fever, in four patients; ataxia, in two patients; hearing impairment, in one patient; dysarthria, in one patient; and hemiparesis, in one patient. The time interval from the onset of symptoms to the seeking of medical help ranged from 4 to 10 days (mean = 8.9 days).

The initial consciousness levels, imaging severity index (ISI) scores<sup>(8)</sup> and therapeutic outcome of these eight patients are listed in Table 2. The neuroimaging features of Patient 7 (Figure 1) were used as the neuroimaging example of cerebellar BBA, and the ISI scores which included five domains (number, location,



**Figure 1.** Magnetic resonance images (T2-weighted) of Patient 7. Measurement of image severity score (ISI). Single brain abscess (1 point) in the right cerebellar hemisphere (1 point).

The patient's initial GCS score was 15. T2 serial images revealed (a) a brain abscess with largest diameter (25.4 mm, 2 points) and largest midline shift (11.2 mm, 3 points) and (b) largest high-intensity perifocal edema (23.5 mm, 2 points). Total ISI: 1 + 1 + 2 + 3 + 2 = 9 points

diameter, perilesional edema, and midline shift of brain abscess) were used to document and assess the imaging feature. Cerebellar BBA was located in the right cerebellar hemisphere in four patients and in the left cerebellar hemispheres in the other four patients. All patients except Patient 4 had a single abscess. Of the seven patients with single BBA, the BBA of Patient 3 was multiloculated, while that of the others was uniloculated. Besides the mass lesion, hydrocephalus was found in Patients 3, 4, and 6. Apart from antimicrobial treatment, all eight patients underwent a neurosurgical procedure. Patients 2 and 4-8 underwent suboccipital craniectomy with abscess excision, and Patients 1 and 3 underwent abscess aspiration and drainage via burr hole or craniotomy. The implicated pathogens, as listed in Table 1, were found in six patients and were not found in Patients 2 and 3. Patients 1 and 5-7 had a monomicrobial infection while Patients 4 and 8 had a polymicrobial infection. With the effort of both medical and surgical treatment, seven patients survived and Patient 7 died. Patient 7 died immediately after the neurosurgical procedure, which resulted in an acute epidural hemorrhage and hydrocephalus. Of the seven patients who survived, Patients 1, 4, and 5 had a full recovery, Patients 2 and 6 had dizziness, Patient 3 had headache, and patient 8 had ataxia. The therapeutic outcome of these eight patients 1 month after discharge was quantified by the modified Rankin scale (mRS)<sup>(6)</sup>. In this study, a "good outcome" was defined as normal state or mild neurologic deficit (mRS 0-2), while a "poor outcome," as an obvious sequel or death (mRS  $\geq 3$ )<sup>(6)</sup>. Patients 1-6 had a good prognosis and Patients 7 and 8 had a poor prognosis. Patient 3 had recurrent cerebellar abscess 20 months after discharge.

## DISCUSSION

This study revealed that solely cerebellar BBA accounted for 3.8% (8/210) of the overall BBA cases found in the study period and this figure of incidence is relatively lower than those (4-12%) in other reports<sup>(4,6,7)</sup>. The onset age of cerebellar BBA of these eight patients can be divided into two groups, namely, the pediatric group (Patients 1 and 6, mean age = 9.5 years) and the

adult group (Patients 2-5, 7, and 8, mean age = 45.7 years). This distribution is similar but not exactly the same as the bimodal distribution of cerebellar abscess reported by Mathisen et al.<sup>(2)</sup>.

In this study, dizziness was found to be the most common clinical symptom of cerebellar BBA, and the other common symptoms were headache, altered consciousness, and fever. These signs and symptoms are not unique and can be seen in other neurologic disorders. In the studies of overall BBA<sup>(1,4,6,7)</sup>, headache, fever, focal neurologic deficit, and altered consciousness are the common clinical symptoms, while dizziness is not as common. The high incidence of dizziness, as shown in this study, may deserve notification in the diagnosis of cerebellar BBA. In one study of cerebellar abscess<sup>(9)</sup>, early diagnosis, especially within two weeks of symptom onset, is an important prognostic factor. The cerebellar BBA of Patients 1-6 was diagnosed within 10 days (4-10 days) and they all survived. The cerebellar BBA of Patient 8 was diagnosed at about 20 days after the onset of the symptom; she eventually had a poor outcome, as assessed with mRS. This result of the outcome of these eight cerebellar BBA patients seems to have a positive correlation with the speculation of Shaw et al.<sup>(9)</sup>.

Contiguous infection, especially of otogenic source, is the most important predisposing factor of cerebellar abscess<sup>(2,9-12)</sup>. In this study, contiguous infection from a nearby infectious site was found in three patients (Patients 2, 6, and 8), accounting for 37.5% (3/8) of the cases. The other five patients (Patients 1, 3-5, and 7) probably had a hematogenous spread of infection, accounting for 62.5% (5/8) of the cases. This relative frequency of contiguous and hematogenous infection is not consistent with that reported in the study of Shaw et al.<sup>(9)</sup>, in which they found a 93% incidence of nearby otogenic disease. This difference may be due to the relatively high incidence of association with other medical problems such as diabetes mellitus and cardiac diseases in our patients. The implicated pathogens of pyogenic brain disorders are known to have a close relationship with various predisposing factors<sup>(2,10,12)</sup>. In this study, positive cultures were found in 75% (6/8) of the cases, while no growth was observed in 25% (2/8) of the cases.

This relative frequency of the culture rate is consistent with that in other reports<sup>(1,5-7,11)</sup>. Many factors can be related to the result of sterile culture in BBA, of which early or previous use of adequate antimicrobial agent may be an important one<sup>(2,7)</sup>. Of the six patients with a positive culture of pathogens, four patients had a monomicrobial infection, while two patients had a polymicrobial infection. In this study, polymicrobial infection accounted for 25% (2/8) of the cerebellar BBA

cases and this figure of incidence is also consistent with that in other BBA studies<sup>(1,5-7,11)</sup>. In the study, we also found that streptococcal species were the most common implicated pathogens among those with a positive culture.

Early craniectomy with excision or aspiration combined with the use of antimicrobial agents is strongly suggested for the treatment of cerebellar BBA<sup>(2,10,13)</sup>. Owing to this critical consideration, all eight patients, as

**Table 1.** Basic clinical data of the 8 patients with cerebellar bacterial brain abscess

Pt	Sex / Age (years)	Manifestation / duration (days)	Underlying condition	Pathogen	Surgical procedure / antibiotic / duration of antibiotic use (days)
1	M / 6	Headache, fever, altered consciousness / 10	TOF, recent tooth extraction	Aerobic	Aspiration / PCN G ( $1.5 \times 10^6$ U, Q4H) + CM (400 mg, Q6H) / 28
2	M / 35	Dizziness, ataxia / 4	Cholesteatoma s/p mastoidectomy	No growth	Excision / PCN G ( $3 \times 10^6$ U, Q6H) + GM (60 mg, Q8H) / 22 → CEX (250 mg, QID) / 14
3	M / 49	Headache, fever, dizziness, hearing loss / 5	Diabetes mellitus, cirrhosis	No growth	Aspiration / CIP (500 mg, BID) / 84 → CEX (500 mg, BID) / 72
4	M / 51	Headache, altered consciousness, dizziness, ataxia, dysarthria / 10	-	Peptostreptococcus micros Viridans streptococcus Pseudomonas aeruginosa	Excision / PCN G ( $3 \times 10^6$ U, Q4H) + GM (60 mg, Q8H) + CM (1 gm, Q8H) / 38 → CC (150 mg, QID) / 89
5	M / 47	Headache, fever, altered consciousness, dizziness, ataxia, hemiparesis / 7	-	Viridans streptococcus	Excision / PCN G ( $3 \times 10^6$ U, Q4H) / 8 → AMP (500 mg, Q6H) / 32
6	F / 13	Altered consciousness, dizziness / 5	Acute otitis media	Group A streptococcus	Excision / VA (500 mg, Q12H) + MET (350 mg, Q6H) / 4 → PCN G ( $6 \times 10^6$ U, Q6H) / 31
7	F / 38	Headache, fever, dizziness / 10	TR with right-to-left shunt	Viridans streptococcus	Excision / VA (1 g, Q12H) + CAZ (2 g, Q8H) / 14
8	F / 54	Altered consciousness, dizziness / 20	Diabetes mellitus, mastoiditis	Peptostreptococcus micros Enterococcus faecalis Enterococcus casseliflavus Fusobacterium spp. Shewanella putrefaciens	Excision / VA (1 g, Q12H) + CAZ (2 g, Q8H) / 12 → MET (0.5 g, Q8H) + CRO (2 g, Q12H) / 32 → AMP (2 g, Q6H) + CAZ (2 g, Q8H) / 39

Pt = patient; M = male; F = female; TOF = tetralogy of Fallot; s/p = post state; TR = tricuspid regurgitation; PCN G = penicillin G; CM = chloramphenicol; GM = gentamycin; CIP = ciprofloxacin; CC = clindamycin; AMP = ampicillin; VA = vancomycin; MET = metronidazole; CAZ = ceftazidime; CRO = ceftriaxone; CEX = cephalexin; → = shift to.

**Table 2.** The score of GCS, ISI, and mRS of the 8 patients with cerebellar bacterial brain abscess

Pt	Initial GCS	Number	ISI Score				Total score	Outcome (mRS)
			Location / score	Diameter (mm) / score	Perilesional edema (mm) / score	Midline shift (mm) / score		
1	E2V3M5 (10)	1	L / 1	52.9 / 3	17.6 / 1	9.4 / 2	8	0
2	E4V5M6 (15)	1	R / 1	12.3 / 1	7.2 / 2	1.6 / 1	6	1
3	E4V5M6 (15)	1 (multiloculated)	L / 1	60.4 / 3	25.3 / 1	22.2 / 3	9	1
4	E4V4M6 (14)	4 (multiple)	R / 1	30.4 / 2	19.8 / 2	15.5 / 3	12	0
5	E3V5M6 (14)	1	L / 1	33.2 / 2	17.0 / 2	5.4 / 2	8	0
6	E3V4M6 (13)	1	L / 1	36.5 / 2	34.1 / 2	17.0 / 3	9	1
7	E4V5M6 (15)	1	R / 1	25.4 / 2	23.5 / 2	11.2 / 3	9	6
8	E4V4M6 (14)	1	R / 1	35.3 / 2	21.5 / 2	13.8 / 3	9	4

GCS = Glasgow coma scale; L = left cerebellar hemisphere; R = right cerebellar hemisphere; ISI = imaging severity index; mRS = modified Rankin scale.

shown in Table 1, received a neurosurgical procedure for treatment. The therapeutic result of these eight cerebellar BBA cases revealed a survival rate of 87.5% (7/8), and 85.7% (6/7) of the survivors, as shown in Table 2, had a good recovery state. Many factors have been known to be linked to the prognosis of BBA<sup>(1,2,5,7,8,10)</sup>. In the study of Demir MK et al.<sup>(8)</sup>, the therapeutic outcome was significantly worse in patients with initial ISI > 8 points (cut-off value) or GCS scores < 13 points (cut-off value). If Patient 7 is excluded from consideration, 85.7% (6/7) of the cases had an initial GCS score  $\geq$  13 (Table 2); this finding of initial GCS scores is consistent with the outcome prediction reported by Demir MK et al.<sup>(8)</sup>. In this study, the ISI scores of the seven survivors (Table 2) were 8 in six patients and less than 8 in one patient, and this finding of ISI scores is not consistent with the outcome prediction reported by Demir MK et al.<sup>(8)</sup>. Patient 3 had "multiloculated" BBA and received "aspiration" as the neurosurgical procedure, and the patient had a recurrence of cerebellar BBA eventually. Clinically, the recurrence rate of overall BBA is between 10% and 50%<sup>(10,14)</sup>, while that of cerebellar BBA is 21%, as reported by Shaw et al.<sup>(9)</sup>. In one study of multiloculated BBA<sup>(15)</sup>, Su et al. found that the recurrence rate of multiloculated BBA was higher than that of uniloculated BBA, especially when the neurosurgical procedure "excision" was

not performed and only "aspiration" was performed.

In conclusion, solely cerebellar BBA accounted for 3.8% (8/210) of the overall BBA. In cerebellar BBA, dizziness is a frequent symptom. Early diagnosis and a combination of antimicrobial and neurosurgical intervention is important for its treatment. This study is limited by its small case number; therefore, further large-scale study of cerebellar BBA is needed for a better delineation of the clinical characteristics, therapeutic outcome, and prognostic factors.

## REFERENCES

1. Lu CH, Chang WN, Lin YC, Tsai NW, Liliang PC, Su TM, Rau CS, Tsai YD, Liang CL, Lee PY, Chang HW, Wu JJ. Bacterial brain abscess: microbiological features, epidemiological trends and therapeutic outcomes. *QJM* 2002;95: 501-509.
2. Mathisen GE, Johnson JP. Brain abscess. *Clin Infect Dis* 1997;25:763-779.
3. Lee TH, Chang WN, Su TM, Chang HW, Lui CC, Ho JT, Wang HC, Lu CH. Clinical features and predictive factors of intraventricular rupture in patients who have bacterial brain abscesses. *J Neurol Neurosurg Psychiatry* 2007; 78:303-309.
4. Kao PT, Tseng HK, Liu CP, Su SC, Lee CM. Brain abscess:

- clinical analysis of 53 cases. *J Microbiol Immunol Infect* 2003;36:129-136.
5. Tattevin P, Bruneel F, Clair B, Lellouche F, de Broucher T, Chevret S, Bedos JP, Wolff M, Regnier B. Bacterial brain abscesses: a retrospective study of 94 patients admitted to an intensive care unit (1980 to 1999). *Am J Med* 2003; 115:143-146.
  6. Çavuşoğlu H, Kaya RA, Türkmenoğlu ON, Çolak I, Aydın Y. Brain abscess: analysis of results in a series of 51 patients with a combined surgical and medical approach during an 11-year period. *Neurosurg Focus* 2008;24:E9.
  7. Tonon E, Scotton PG, Gallucci M, Vaglia A. Brain abscess: clinical aspects of 100 patients. *Int J Infect Dis* 2006;10: 103-109.
  8. Demir MK, Hakan T, Kilicoglu G, Ceran N, Berkman MZ, Erdem I, Goktas P. Bacterial brain abscesses: prognostic value of an imaging severity index. *Clin Radiol* 2007;62: 564-572.
  9. Shaw MD, Russell JA. Cerebellar abscess: a review of 47 cases. *J Neurol Neurosurg Psychiatry* 1975;38:429-435.
  10. Erdoğan E, Cansever T. Pyogenic brain abscess. *Neurosurg Focus* 2008;24:E2.
  11. Sennaroglu L, Sozeri B. Otogenic brain abscess: Review of 41 cases. *Otolaryngol Head Neck Surg* 2000;123:751-755.
  12. Sheehan JP, Jane JA, Ray DK. Brain abscess in children. *Neurosurg Focus* 2008;24:E6.
  13. Lu CH, Chang WN, Lui CC. Strategies for the management of bacterial brain abscess. *J Clin Neurosci* 2006;13:979-985.
  14. Faraji-Rad M, Samini F. Clinical features and outcome of 83 adult patients with brain abscess. *Arch Iran Med* 2007; 10:379-382.
  15. Su TM, Lan CM, Tsai YD, Lee TC, Chang WN. Multiloculated pyogenic brain abscess: experience in 25 patients. *Neurosurgery* 2003;52:1075-1079.